

Title: Automatic bone and tooth detection for CT-based dental implant planning

Authors: Nguyen The Duy, Hans Lamecker, Dagmar Kainmueller, Stefan Gumhold, Stefan Zachow

### Purpose

According to the American Academy of Implant Dentistry (AAID) the number of patients with bone-anchored dental implants is growing year by year. The goal is to reduce the costs of implant procedures and material, and at the same time ensuring implantation longevity, as well as patient safety and comfort. During surgery, the task is to place an implant into the bone in a stable manner and so that vital structures, such as dental roots, the inferior alveolar nerve, the sinus or major blood vessels are not damaged. One approach to achieve this goal are personalized surgical drill guides. These mechanical components are manufactured specifically for a given patient and can either be placed on top of the bone, gum or teeth. They must be designed accurately to obtain a stable implant position and to prevent the surgeon from damaging vital structures. A prerequisite for such a design is a pre-operative imaging of the relevant structures. Panoramic X-rays (orthopantomograms) are the predominant imaging technique in practice, but lack full three-dimensional (3D) information. 3D-imaging, however, becomes more and more accessible through the use of cone-beam CT data (CBCT or DVT). Hence, the task is to extract an accurate geometric representation of the relevant anatomical structures from such image data (segmentation). While CBCT is suitable for dental applications due to its small field of view and low dosage applied to the patient, it is less accurate than conventional CT and more prone to imaging defects such as noise and metal artifacts from dental fillings and brackets. This makes manual segmentation even more difficult and laborious. In this work, we present an automatic method for segmentation of all relevant structures of the jaw from CT data. This includes the mandibular and maxillary bone, the alveolar nerve and the overall detection and identification of existing (or missing) teeth. The only component missing in our work so far is an accurate segmentation of individual teeth (roots and crowns). Based on our tooth detection method, however, we are confident that this step can be reliably implemented in a future study.

### Methods

We use a statistical shape model (SSM) approach for the segmentation of the jaws. Our framework is based on the work of Kainmueller et al.[1], who used SSMs for the segmentation of the mandibular bone. In the first step, we build an SSM for mandible and maxilla from manually segmented CT and CBCT datasets (43 for maxilla, 107 for mandible). Afterwards, segmentation procedure involves adapting the SSM's shape and transformation parameters in order to achieve the best fit into image data. Furthermore, we have developed a strategy for maxilla segmentation in order to segment the bone in the tooth region dealing with interfering teeth and metal artefacts. The technical details of this approach are described in another publication. The bone segmentation results are used as an initialization for the detection of the remaining structures, such as the nerve and teeth.

In order to reconstruct the alveolar nerve, we use the approach described by Kainmueller et al.[1]. The idea behind is to use the region of the segmented mandible as a rough initialisation and refine the reconstruction in the vicinity of the initial guess using graph-based optimisation. For tooth detection, we use the adapted SSM to automatically extract the region containing the row of teeth. Our method then automatically splits the row of teeth into 16 *subregions* - each either containing a specific tooth or representing a specific missing tooth. The division is done by estimating 15 separation planes, i.e. the boundaries between two neighbouring subregions. Prior knowledge about tooth widths is encoded by constraining distances between neighbouring separation planes according to the widths of their corresponding teeth. The separation task is formulated as a discrete optimization problem which is efficiently solved using Dijkstra's algorithm. Finally, we apply a classifier on each subregion to decide whether it contains a tooth or not. Detected teeth can be identified using the correspondence between subregion and tooth class. We use the classification algorithms AdaBoost.M1 and Support Vector Machines with intensity histograms of the subregions as features.

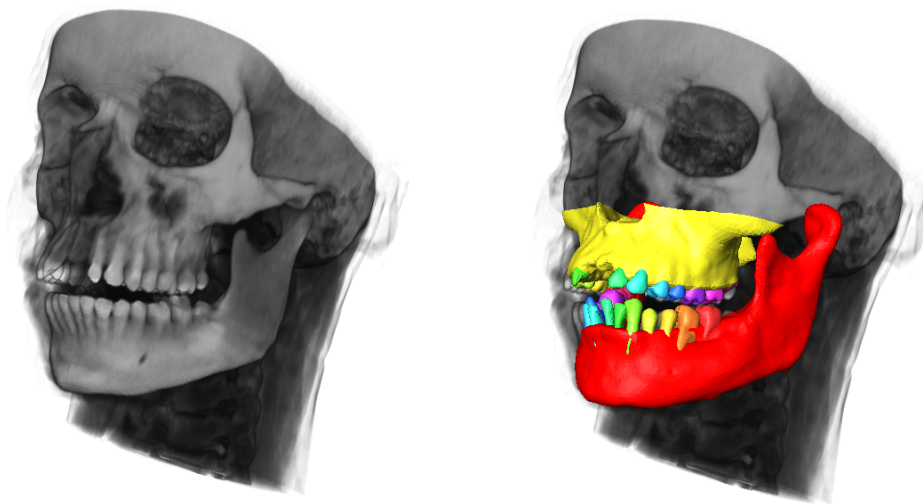


Fig. 1 Left: Input of the algorithm is the CT image. Right: Output - segmented jaws (red and yellow) and detected and identified teeth (marked by different color).

## Results

In our experiments, we achieved a segmentation accuracy of  $0.5 \pm 0.1\text{mm}$  for the mandibular bone and  $0.5 \pm 0.5\text{mm}$  for the maxillary bone surface distance between our adapted SSM and the ground truth surface. The nerve was reconstructed with an average error of  $1.0 \pm 0.6\text{mm}$ . We used CT images in our maxilla segmentation experiments and CBCT images for mandible segmentation tests. The voxel-size of these images ranged from 0.3mm - 0.5mm.

We validated tooth separation and detection on 39 CT datasets in case of the upper teeth. In each round, we used 34 or 35 datasets to train the tooth separator and classifier. Afterwards,

we tested them on the remaining 4 or 5 datasets. In order to measure separation quality, we compute the ratio between subvolume of a tooth lying in the correct region and its total volume. Our tooth separation algorithm isolated teeth with a volume ratio of 39% – 96%.

Finally, our classifiers achieved a classification rate of 51% to 96%. Tooth classification rate was dependent on the performance of the tooth separation algorithm. However, when separation quality exceeds a ratio of 60%, classification rate increased to approximately 92% in all experiments.

### Conclusion

We have proposed a method which is able to automatically segment jaws and detect upper teeth in CT and CBCT images. Experimental results show that the approach accurately segments the maxilla bone and teeth can be precisely located in the CT image. Since we do not use maxilla specific information, our tooth detection methods may be transferred to the lower jaw. Future work is supposed to integrate shape features into tooth detection in order to deal with cases where teeth have shifted too far away from their original position. Moreover, we plan to use the tooth detection results to initialize a tooth segmentation routine to determine the exact tooth boundaries.

[1] D. Kainmueller, H. Lamecker, H. Seim, M. Zinser, S. Zachow:  
Automatic Extraction of Mandibular Nerve and Bone from Cone-Beam CT Data  
Proc. Medical Image Computing and Computer Assisted Intervention (MICCAI) (G.-Z. Yang et al., eds.).  
pp. 76-83, 2009.